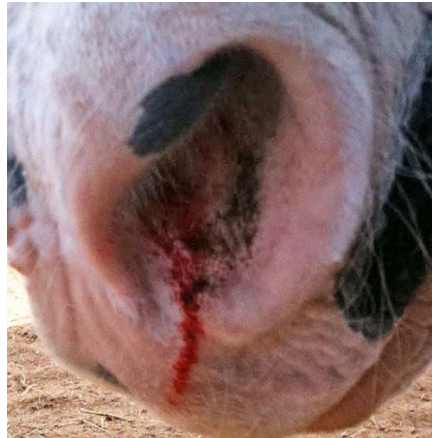

My Horse has a bloody nose

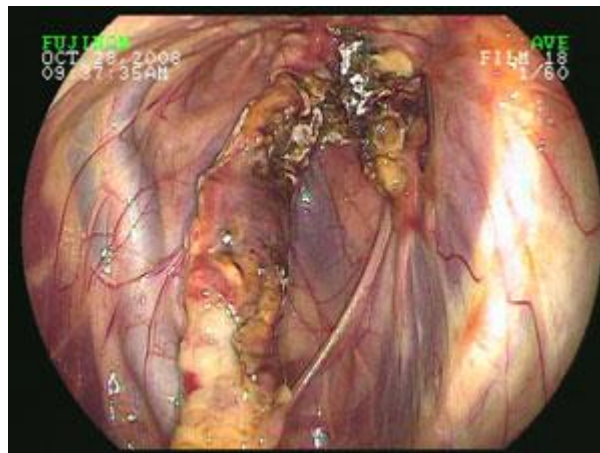
Dr. Chris Bell BSc, DVM, MVetSc, DACVS

There are several different reasons for your horse to develop a bloody nose and the differences can be very important to understand in order to properly care for your horse. Bleeding can come from one or both nostrils and can be colored anywhere between bright red to brown to black depending on where it came from in the horse's body. The bleeding may be associated with an obvious cause such as a trauma to the head or there may be no known reason for the presence of blood in the nostril. Some nose bleeds can be life threatening so knowing some of the different signs and symptoms of the various nose bleed conditions is important.



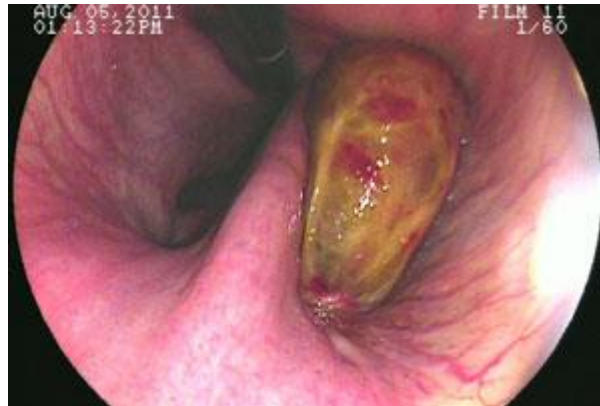Facial or head trauma is a very common reason for a nose bleed in the horse. This can be as simple as a bunt to the head of another horse or as severe as flipping over backwards in the cross ties and hitting their head on the ground. Simple trauma results in rupture of the small blood vessels inside the nose. Usually there is bleeding in a small amount from only one side of the nostrils. It usually stops soon after the trauma happens and often times, these nose bleeds go unnoticed and resolve on their own. When a horse flips over backwards and hits its head, the large muscles in the neck and poll tense and are held in contraction. A portion of these muscles attach to the base of the skull at the basisphenoid bone and these muscles have the power to tear the blood vessels within the base of the skull as well as the guttural pouches. In addition, these muscles can avulse or tear off the basisphenoid bone and thus expose the base of the brain to the inside of the guttural pouches. This type of trauma results in profuse hemorrhage which is usually seen from both nostrils and can be fatal. In some horses, the bleeding is delayed until the horse stands after the fall and in others, the bleeding rapidly ensues the fall. In the case of simple trauma related nose bleeds, most times, cautious monitoring of the horse for 10-15 minutes will be suffice to ensure that there is no further bleeding. If the trauma involved a more significant blow to the head such as a kick, then a veterinarian should be summoned to identify any fractures to the skull which may not be evident. In the case of severe trauma, a veterinarian should be called immediately and all efforts to minimize suffering of the horse should be taken if the bleeding cannot be controlled. There is no effective means to provide direct pressure to the base of the skull in horses without compromising their airway. If the horse is able to stand after a fall and the bleeding stops within 2-3 minutes, then the likelihood of a fatal bleed out is lessened, however, the horse will require intensive medical management to return to health.

Another common cause of nose bleeds is a fungal infection of the guttural pouch(es). This is also referred to as guttural pouch mycosis. With this condition, a common fungus begins to grow within the guttural pouch of the horse. In the horse, there are two guttural pouches, one on each side of the pharynx. These pouches are actually enlarged outcroppings of the Eustachian tube (hearing tube – the thing you ‘pop’ in the airplane to equalize the pressure in your ear). In the horse, this guttural pouch contains a large number of very important anatomical structures including several cranial nerves and the internal carotid artery and maxillary artery. In guttural pouch mycosis, the fungus has a predilection for growing on the internal carotid artery and occasionally on the maxillary artery as well. As it grows, it eats the wall of the artery away until one day, when the wall ruptures and the internal carotid artery begins to bleed uncontrollably. In these horses, you will notice profuse bright red blood from one nostril (and occasionally both nostrils). The side of the bleeding is the side of the guttural pouch effected. The guttural pouch will fill with blood and in most cases during the first bleed, the blood will clot and stop bleeding. However, if the first bleed is not detected by the horse owner, the fungus will continue to grow and eventually a second fatal bleed will occur from the same artery. It is very important, that if your horse develops a profuse bleeding nose without any history of trauma, that you contact your vet right away to determine whether the guttural pouch may be involved. The diagnosis is made by use of an endoscope to look for the fungus. There are several treatments, including daily lavage of the fungus with anti-fungal medications, however, surgical occlusion of the internal carotid artery is by far the best method to manage these cases to prevent future problems.

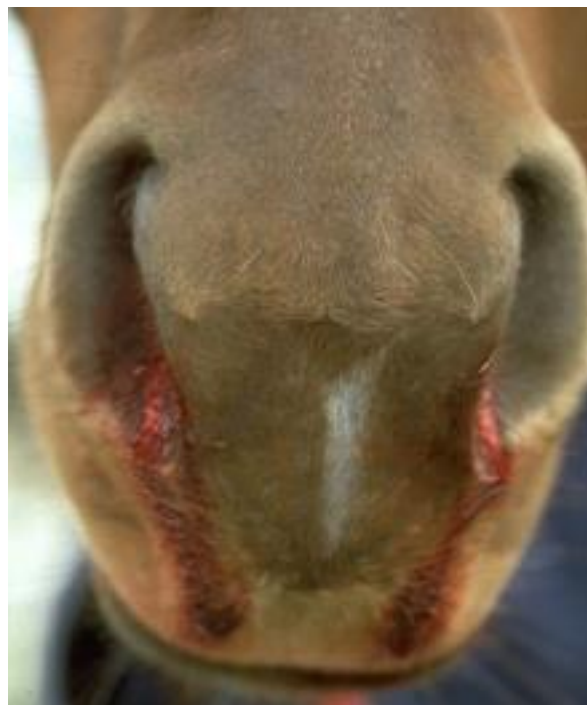

Ethmoid hematomas are a benign tumor of the head and can involve both the nasopharynx and the sinuses. These tumors are enlarged vascular masses that protrude from the ethmoids and result in brown nasal discharge which usually comes from only one nostril. As these masses grow, they rupture and bleed. They can also partially or fully occlude the nasal passage on the affected side of the head. The mass can begin inside the sinus or through the back of the nasal passage (nasopharynx). When these masses involve the sinus, they can be much more difficult to detect. The means of diagnosing these tumors is with an endoscope and looking for the characteristic brown/yellow-green membrane over the affected ethmoid. In the case of sinus involvement, radiographs are needed to identify the mass and in many cases a CT (computed tomography) scan is needed. The treatment for these tumors is either medical management or surgical removal of the tumor. With medical management, a coagulating agent such as formalin is injected into the mass to cause regression. If medical management fails or the mass involves the sinus, then the tumor must be removed surgically. The success rate with medical

management is about 60-70% and with surgical treatment it is about 80%. There is a possibility of recurrence of the tumors in about 20-30% of cases.

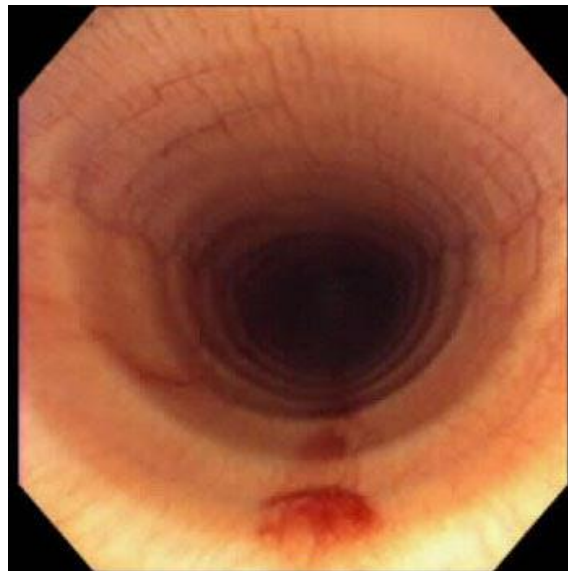


There are several other rarer causes of nose bleeds originating in the upper airways such as infection related nose bleeds which usually contain pus or yellow mucous with the blood in the nose and rare malignant tumors of the head such as squamous cell carcinomas in the sinuses. Again, a thorough clinical exam with an endoscopic view of the upper airway will often yield the cause of the problem, however, in some cases xrays, CT and MRI's may be necessary.



The other major cause for nose bleeds in horses is exercised induced pulmonary hemorrhage (EIPH). This is where blood from the lungs is coughed up or expelled from the nostrils after exercise. This can come from one nostril only but more commonly from both. The blood may occur immediately after or during the exercise and the color can be red to brown depending on how long after the exercise the blood is seen. This type of bleeding occurs from the lower airways or lungs. It is the result of excessive shear forces on the vascular tissues of the lungs – thin walled blood vessels that are stretched during

exercise. As these vessels break, the blood is expelled into the bronchioles and then into the trachea and out the nostrils. There are many factors that play into whether or not your horse will develop EIPH. It is common in Thoroughbreds and Standardbreds but can be seen in competitive Quarter Horses such as barrel racing horses. The severity of the condition can be graded based on the amount of blood produced and where it is seen. Horses with low grade EIPH will only have blood seen on endoscopy of the lower end of the trachea and then there are various degrees of severity that increase as the amount of blood present increased up the trachea until it is physically running from the nose. The diagnosis of EIPH is made with a complete history of exercise, endoscopic exam of the upper and lower airways, and bronchoalveolar lavage (BAL). Once diagnosed, there are several options to treat EIPH, however, due to the nature of the scar tissue that forms within the ruptured vessel walls, horses often have chronic episodes of EIPH even with much rest. The management of a horse with EIPH needs to include resting the lungs from exercise for up to 6 months in severe cases. Some horses can be managed with diuretics such as furosemide (Lasix or Salix). This is used to decrease the amount of fluid pressure in the blood stream and thus thought to decrease the likelihood of hemorrhage from the lung blood vessels during exercise. Unfortunately, this treatment is only about 65-70% effective to eliminating the hemorrhage. Many other non-licensed products are on the market to attempt to prevent bleeding in EIPH horses, few work any better than nothing at all. Horses that have bled from their lungs will need rest from exercise for a minimum of 8 weeks. Most commonly, horses that have recently exhibited bleeding from the nostrils or diagnosed with a recent bleed will be put on antibiotics due to the high risk of pneumonia developing post bleed.



Any horse with blood present in their nose should be closely monitored and if the bleeding does not stop or the horse is showing any other signs of injury/illness such as a fever, difficulty breathing or incoordination, then a veterinarian needs to see them immediately. Some nose bleeds are minor but knowing the other possible causes is important in helping make the decision on when to deal with this on your own and when to call the vet.